

## FIBULAR AUTOSTRUTGRAFT AS THE OPTIONAL TREATMENT OF THE FEMORAL NECK FRACTURES IN SURABAYA

**Achmad Sjarwani**

Department of Orthopaedic & Traumatology

Airlangga University School of Medicine

Dr Soetomo Teaching Hospital, Surabaya

### ABSTRACT

*Fractures of the femoral neck have always been a great challenge to orthopaedic surgeons. The main aim of the treatment is to retain the femoral head and to ensure that the hip is stable, painless, and mobile. Compression screw fixation with fibular autostrutgraft method give some evidence of reconstitution of the trabecular pattern, incorporation of the fibula into the femoral head proximal to the fracture line, and little or no progression of structural collapse after a sufficiently long period of follow-up. We measure Hip Score for the patients with femoral neck fractures after treated by open reduction, cancellous screw fixation and free fibular grafting. Hip Score including pain, range of hip movement, ability to work and leg length discrepancy. The results were classified as excellent, good, fair or poor. Anteroposterior and axial radiographs of the hip were also assessed and obliteration of the fracture site with trabecular bridging was taken as evidence of union. At the last 3 years we treat 15 patients with neglected femoral neck fracture by cancellous screw fixation and free fibular autostrutgraft construct. 9 patient is neglected fracture and the rest is fresh fractures. 10 patients were found to be united and the other was still in observation. For that 10 patients, we evaluate with Hip Score. Hip score was excellent in 6 patients, good in 3 patients, and poor in 1 patient. There are significance improvement of the union rate and hip function of the patients with femoral neck fracture that treated by compression screw fixation with fibular autostrutgraft method.*

**Keyword:** Femoral neck fracture, fibular autostrutgraft, hip score

**Correspondence:** Achmad Sjarwani, Department of Orthopaedics, Airlangga University School of Medicine  
Dr Soetomo Teaching Hospital, Jl Prof Dr Moestopo 6-8, Surabaya, Ph. 62-31-5501481, email: ortopedi@rad.net.id

### INTRODUCTION

Fractures of the neck of the femur remain in many ways today the unsolved fracture as far as treatment and results are concerned. With life expectancy increasing with each decade, significant numbers of hospitalized and nursing home patients suffering from femoral neck fractures and their sequelae. Femoral neck fractures in young patients usually are caused by high-energy trauma and often are associated with multiple injuries and high rates of avascular necrosis and nonunion. Hip fractures have a bimodal age distribution: Approximately 97% occur in patients over 50 years of age (the incidence increases with age), and only 3% in patients under 50. In the latter group, they occur most commonly between 20 and 40 years of age, usually in men, and are due to high-energy trauma associated with sports and industrial and motor-vehicle accidents. In this young group, most hip fractures are subtrochanteric or basicervical. In contrast, fractures of the hip in patients between 40 and 50 years of age usually occur in alcoholics or patients with multiple medical diseases, whose fractures are related to osteoporosis. In underdeveloped countries, because of poverty,

ignorance and lack of facilities, these fractures are often seen only after either a delay or improper treatment.

### ANATOMY AND VASCULARIZATION OF THE FEMORAL NECK

The femoral side of the hip is made up of the femoral head with its articular cartilage, and the femoral neck, which connects the head to the shaft in the region of the lesser and greater trochanters. The synovial membrane incorporates the entire femoral head and the anterior neck, but only the proximal half of the neck posteriorly. A substantial synovial membrane covers the entire anterior femoral neck, but only the most proximal half posteriorly. The femoral neck has a wide variability in length and shape. There is a large posterior overhang of the greater trochanter, which locates the femoral neck in the anterior half of the proximal femur when viewed from the lateral orientation, a fact that must be recognized for the accurate placement of internal fixation devices.

The shape and size of femoral necks vary widely. The neck–shaft angle does not vary much, however, and is approximately  $130^{\circ} \pm 7^{\circ}$ . Anteversion of the femoral neck is  $10^{\circ} \pm 7^{\circ}$  in normal individuals, with no variation between the sexes. The diameter of the femoral head ranges from 40 to 60 mm, depending on the size of the individual. The thickness of the articular cartilage varies from 4 mm at the apex of the head to 3 mm at the periphery.

The vascular supply to the femoral head arises from three sources. In the majority of persons, the major blood supply to the head comes via the lateral epiphyseal vessels, which penetrate into the bone of the femoral head at its junction with the neck. These vessels are supplied by the subsynovial intracapsular arterial ring, which derives from the ascending cervical arteries that running beneath the synovium of the femoral neck.

These vessels originate from the extracapsular arterial ring, which is primarily the termination of the medial femoral circumflex artery on the posterior aspect of the hip along the intertrochanteric basicervical line. The lateral femoral circumflex artery on the anterior aspect of the neck also contributes to this blood supply; however, the medial femoral circumflex artery usually dominates.

The artery of the ligamentum teres usually originates from the anterior obturator artery but it contributes to the blood supply of only a small area of the femoral head near the attachment of the ligamentum teres. Intraosseous cervical vessels derived from the femoral neck also penetrate into the femoral head but are not the major blood supply.

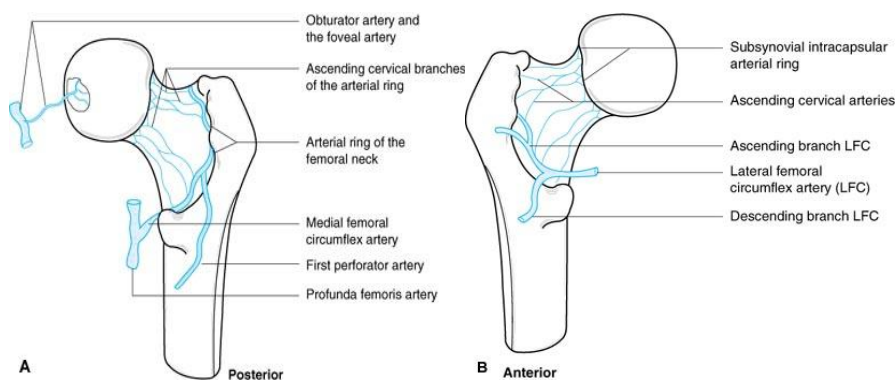


Figure 1. Posterior (A) and anterior (B) views of the hip, showing the extraosseous blood supply to the femoral head.

## EFFECT OF FEMORAL NECK FRACTURE ON VASCULAR SUPPLY

A femoral neck fracture produces a devastating effect on the blood supply to the femoral head. Displacement generally correlates with the severity of the damage to the major blood supply, which is the lateral epiphyseal artery system. Optimal reduction of the femoral neck fracture has been shown in numerous studies to be associated with a lower incidence of femoral head avascular necrosis. This may be a result of the fact that all of the vessels of the lateral epiphyseal artery system may not be torn and that reduction may “unkink” some vessels or, when performed beyond the acute phase, may allow for rapid arterial recanalization.

The method of fixation also influences vascularity to the femoral head. Fixation devices placed in the superior lateral aspects of the femoral head can inadvertently injured the lateral epiphyseal vessels. Devices that are

driven into the head rather than being screwed into the head or inserted in an atraumatic manner can lead to an increased incidence of aseptic necrosis. Twisting of the femoral head while inserting hip screws and using large implants that occupy a substantial cross-sectional area in the femoral neck have also been identified as increasing the incidence of avascular necrosis.

## CLASSIFICATION OF THE FEMORAL NECK FRACTURE

### Anatomic Classification

Fractures of the femoral neck located just distal to that portion of the femoral head covered by cartilage are termed subcapital, fractures in the midportion of the neck are termed transcervical, and those at the base of the neck are termed basilar neck fractures. The first two are intracapsular and the third can be partially

intracapsular and extracapsular posteriorly. Subcapital fractures are at greatest risk for disruption of the blood supply to the femoral head, transcervical fractures have a somewhat lower risk, and the risk is extremely low in basilar neck fractures.

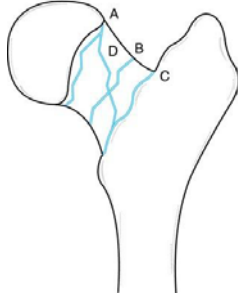


Figure 2. Types of intracapsular fractures of the femoral neck: subcapital (A), transcervical (B), basilar neck (C), and high-angle shear fracture typical of those seen in ipsilateral concomitant fractures of the hip and femoral shaft (D).

### Garden Classification

The Garden classification applies to subcapital fractures and focuses on the degree of displacement. Most orthopaedic surgeons lump Garden stage I and II fractures together as “undisplaced” and Garden stage III and IV fractures together as “displaced.” Undisplaced fractures, if internally fixed in good position and stable, have a favorable prognosis, with union rates of 95% or better and an incidence of avascular necrosis of under 10%, whereas displaced fractures have rates of avascular necrosis as high as 40% (in Garden stage IV fractures) and nonunion rates of 10% or more.

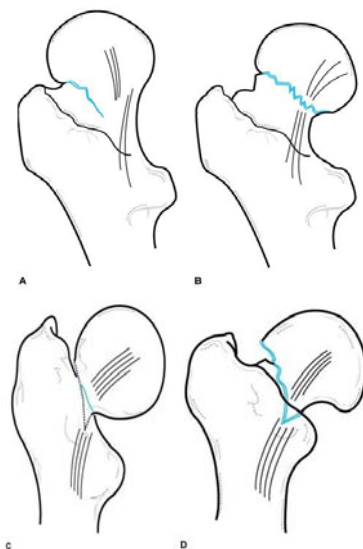


Figure 3. Garden classification of femoral neck fractures. A: Stage I: Incomplete fracture that is abducted and impacted. B: Stage II: Complete fracture without displacement. Note that the compression trabeculae are aligned. C: Stage III: Complete fracture with partial displacement. The neck is still in apposition posteroinferiorly; therefore, the fragments have rotated in opposite directions like two cogwheels. Note that the compression trabeculae are angulated. D: Stage IV: Complete fracture with full displacement. Contact between the fracture surfaces is lost. The distal fragment is in full external rotation and lies anterior to the proximal fragment.

### Pauwels's Classification

Pauwels's classification is based on the angle the fracture line makes with the horizontal. Pauwels's type I fracture is the most horizontal, is often impacted, and therefore with internal fixation tends to stabilize with weight bearing, whereas the Pauwels's type III fracture is nearly vertical, experiences a large degree of shear with weight bearing, and is therefore unstable.

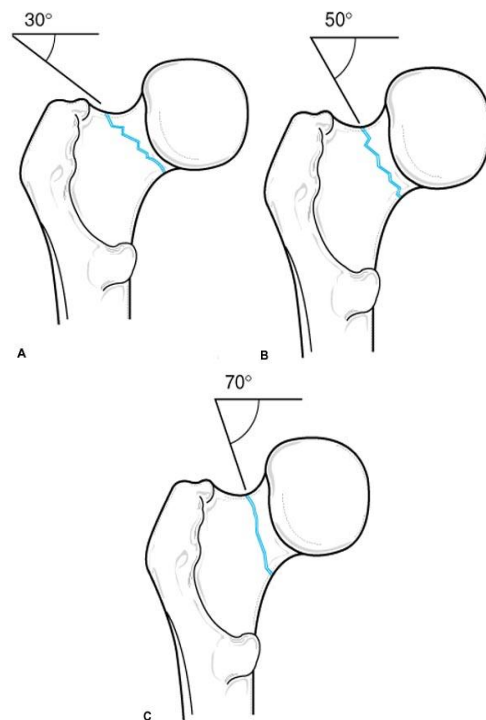


Figure 4. Pauwels's classification of intracapsular hip fractures. A: Type I: Fracture is 30° to 49° from the horizontal. B: Type II: Fracture is 50° to 69° from the horizontal. C: Type III: Fracture is 70° or more from the horizontal.

## Treatment of the femoral neck fracture

Treatment of a femoral neck fracture depends on several factors. The most important criteria to consider are: the amount of displacement of the fracture and the age of the patient

### Operative treatment of the femoral neck fracture

In active adults, try to treat all femoral neck fractures, whether displaced or undisplaced, with internal fixation rather than prosthetic replacement. Even in displaced fractures such as a Garden stage IV where treatment is delayed, good internal fixation in anatomic position usually results in union of the fracture even though the incidence of avascular necrosis may be 40% or more. Many different methods of internal fixation have been used in the past; however, today most surgeons prefer three to four 5–7 mm in diameter lag screws utilizing cannulated screw techniques because of the advantages of placing guide pins prior to the screws. Various types of compression hip screws have also been used. Three cannulated screws routinely and reserve the standard compression hip screw for high shear angle fractures in young vigorous patients for whom the stronger device is needed to resist deforming forces across the fracture site. Augmentation the latter with a 6–7 mm cannulated screw can improve rotational control

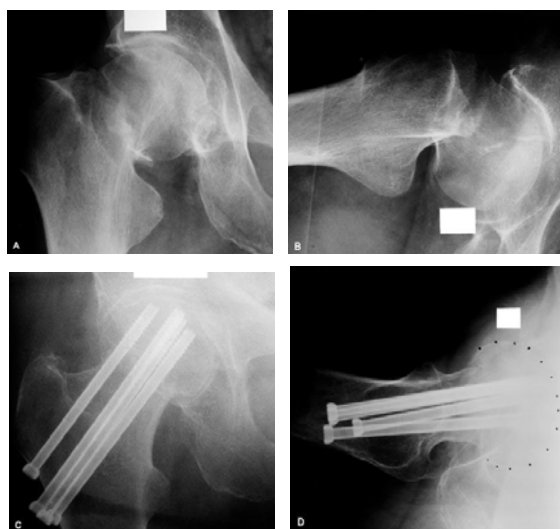


Figure 5. Cannulated screw fixation of a displaced subcapital hip fracture: A: AP radiograph showing a fully displaced Garden stage IV subcapital fracture. B: Lateral radiograph of the displaced fracture. C: AP radiograph after closed reduction and cannulated screw fixation. D: Lateral radiograph after fixation.

For displaced fractures of the femoral neck, reduction, compression, and rigid internal fixation are required if union is to be predictable. Because nonunion and avascular necrosis develop frequently after internal fixation of displaced femoral neck fractures, many surgeons recommend primary prosthetic replacement as an alternative in elderly but ambulatory patients to avoid nonunion and avascular necrosis.

### Relative Indications for Hemiarthroplasty

1. Advanced physiological age. This alone is not a true indication for a prosthesis, although some local and systemic diseases that occur in older patients. Prosthetic replacement probably should be reserved for patients 70 years of age or older with a life expectancy of no more than 10 to 15 years.
2. Fracture-dislocation of the hip in an older individual. If the fracture involves the superior weight-bearing surface of the head

### Stronger Indications for Hemiarthroplasty

1. A fracture that cannot be satisfactorily reduced or fixed with stability, especially with posterior comminution.
2. Femoral neck fractures that lose fixation several weeks after operation.
3. Some preexisting lesions of the hip.
4. Malignancy. A malignancy may be an indication for the insertion of a prosthesis. A patient with a short life expectancy, whether the fracture is pathological or primarily the result of trauma, is best treated with a prosthesis.
5. Neurologic disorders. Patients subject to uncontrolled epileptic seizures and patients with severe uncontrolled parkinsonism are better treated with a primary prosthesis.
6. Old, undiagnosed fractures of the femoral neck.
7. Fracture of the neck of the femur with complete dislocation of the femoral head. This lesion is rare and is best treated by primary prosthetic replacement because avascular necrosis of the head is certain under these circumstances.
8. A patient who probably cannot withstand two operations. If a patient's general condition prohibits a second operation, a primary prosthesis is justified.
9. Patients with psychoses or mental deterioration.

The types of arthroplasty available include unipolar, such as the older Austin Moore or similar prostheses or the newer bipolar prosthesis, including those that can be converted to a total hip. These are available in both cemented and noncemented versions.

## Bone grafting

Bone grafting is a very old surgical procedure. The first recorded bone implant was performed in 1668. Bone grafts are used to treat various disorders, including delayed union and nonunion of fractures, congenital pseudoarthrosis, and osseous defects from trauma, infection, and tumors. Bone grafts are bone that is transplanted from one area of the skeleton to another to aid in healing, strengthening or improving function. Bone grafts are necessary to provide support, fill voids, and enhance biologic repair of skeletal defects.

The ability of bone to heal and of fusions to form is based on three key concepts: osteogenesis, osteoconduction, and osteoinduction. Osteogenesis, defined as the ability to produce new bone, is determined by the presence of osteoprogenitor cells and osteogenic precursor cells in the area. Osteoconductive properties are determined by the presence of a scaffold that allows for vascular and cellular migration, attachment, and distribution. Osteoconductivity refers to the situation in which the graft supports the attachment of new osteoblasts and osteoprogenitor cells. Osteoinductivity refers to the ability of a graft to induce nondifferentiated stem cells or osteoprogenitor cells to differentiate into osteoblasts. Osteoinduction is defined as the ability to stimulate stem cells to differentiate into mature cells through stimulation by local growth factors. Osteoinductive factors including BMPs, TGF- $\beta$ , insulin-like growth factors, acidic and basic fibroblast growth factors (FGF), platelet-derived growth factor, granulocyte colony-stimulating factors. Revascularization of a fresh autograft occurs by micro anastomosis with existing microvessels. This process is more common in cancellous bone and is aided in cortical bone by removal of the periosteum. Most autografts and alloimplants revascularize only by invasion of capillary sprouts from the host bed during the resorption of the old matrix (creeping substitution). Creeping substitution involves invasion of the autograft by osteoclasts, and these, in turn, are followed by a blood vessel bud. New osteons are laid down around the many blood vessels that invade the graft. The ideal grafting material should have osteogenic, osteoconductive, and osteoinductive properties.

In cancellous bone grafts, the necrotic tissue in marrow spaces and haversian canals is removed by macrophages. Granulation tissue, preceded by the advance of capillaries, invades the areas of resorption. Pluripotential mesenchymal cells differentiate into osteoblasts, which begin to lay seams of osteoid along the dead trabeculae of the bone graft. Osteoclasts resorb the necrotic bone, and eventually most of the bone graft

is replaced by new host bone. Finally, the old marrow space is filled by new marrow cells.

In cortical bone, the process of incorporation is similar but much slower, because invasion of the graft must be through the haversian canals of the transplant. Osteoclasts resorb the surface of the canals, creating larger spaces into which granulation tissue grows. As this granulation tissue penetrates the center of the cortical graft, new bone is laid throughout the graft along enlarged haversian canals. Depending on the size of the graft, complete replacement may take many months to a year or more.

Autograft bone is one of the safest to use due to the low risk of disease transmission. It also offers a better chance of acceptance and effectiveness in the transplant site, since it contains the greatest amount of the patients own bone growing cells and proteins. Autograft bone provides a strong framework for the new bone to grow. The graft bone is harvested, or taken, from the bones of the hip, the ribs or the leg.

## Strut graft

May be placed as struts to span fracture gaps and potentially unstable segments. Function primarily in compression, and can be affixed to the proximal and distal segments of recipient bone by screws and cerclage wire. Potential uses for onlay, inlay, stent and strut grafts include spinal fusions, arthrodesis and additional bony support in difficult fractures with limited bone stock such as adjacent to a total hip prosthesis.

## Surabaya experience on fibular autostrutgraft as the treatment of neglected femoral neck fracture

The few reports of neglected fractures of the femoral neck in young adults emphasise that the outcome is usually poor. Early accurate reduction and fixation under compression have given good results, but in underdeveloped countries early operation is not always possible. This can lead to problems of management. It is desirable to try to salvage the femoral head in young adults, and this often calls for some form of bone graft. Lifeso and Young felt that valgus osteotomy gave acceptable results but concluded that nonunion in young adults was difficult to treat. Moreover, displacement osteotomy is no longer popular. The best results come from some form of bone graft with stable fixation. Since Inclan reported revascularisation of the ischaemic femoral head using banked allograft, a variety of bone grafts has been used to achieve union and revascularisation of the femoral head. In 23 cases in which a muscle pedicle graft had been delayed for more than three months after injury, Meyers, Harvey and



Moore found nonunion in 75%. Baksi, Johnson and Brock reported a similar outcome.

Excellent results have been obtained with open reduction and vascularised iliac-crest grafting, but the procedure is technically demanding and few cases have been reported. The incidence of AVN is between 8% and 30% after fracture of the femoral neck, and is probably higher in neglected displaced cases.

The using of fibular graft for the femoral neck fracture introduced first by Nagi et.al in 1981. The fibula is easy to harvest and, provided that sufficient care is taken, leads to minimal morbidity of the donor site. The triffin shape of the fibula stabilize the fracture by preventing rotation and the central part of the fibula ultimately became part of the primary compressive trabeculae of the femoral neck. The fibular graft acts as a 'biological implant' or 'biosynthesis' and avascular heads may revascularize after union.

In Surabaya we treat femoral neck fracture by closed/open reduction, fixation with compression screw and inserting free fibular autograft. For neglected cases it's not possible to achieve accurate reduction by closed methods, and repeated attempts at manipulation can be further harm the blood supply to the head of the femur. Careful open reduction causes only minimal additional insult to the blood supply.

The surgical technique of this method as follows :

1. use orthopaedic table
2. use image intensifier
3. use Watson - jones lateral approach
4. fracture reduced and temporarily fixed with two K-wire parallel in the superior part and inferior part (calcar femorale) of the femoral neck
5. a lag screw with washer inserted just below greater trochanter to fix the fracture
6. assistant harvest the fibula
7. drill with 10 mm diameter drill bit to cut a dowel of bone from the lateral cortex of the trochanter just above the screw head to make a tunnel for the fibular graft
8. the graft is then hammered into tunnel
9. no need the cast

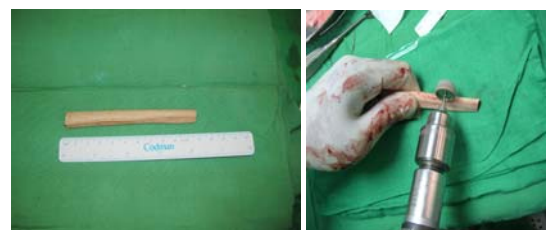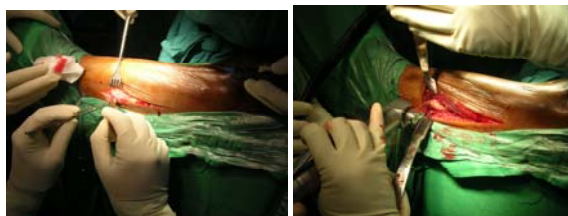


Figure 6. Harvesting of the fibula from ipsilateral side

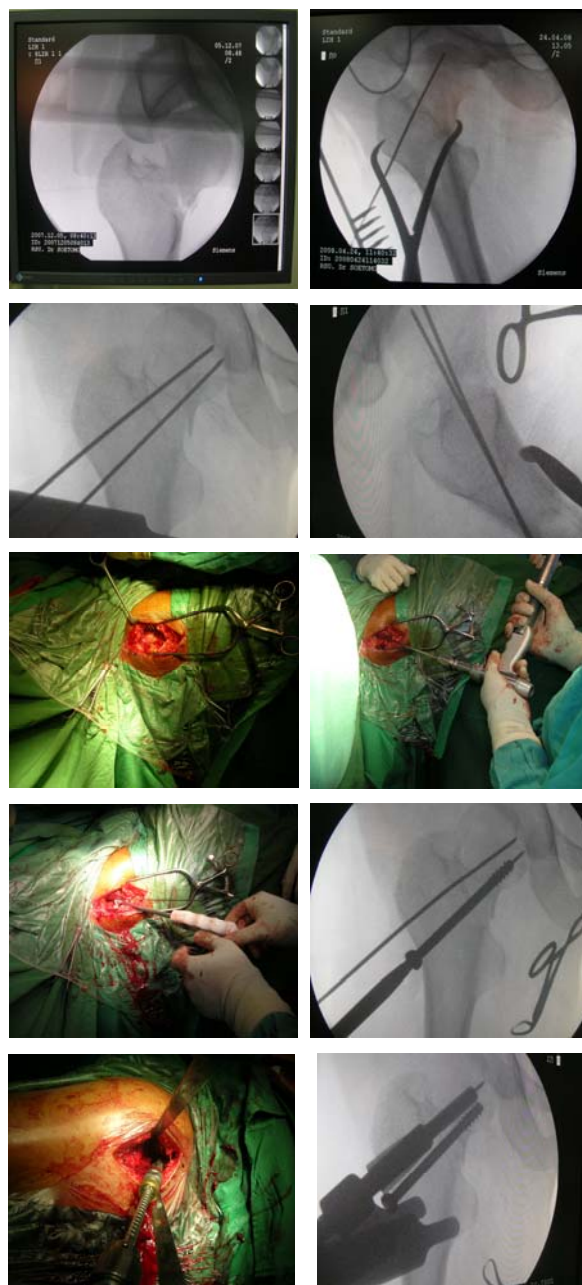

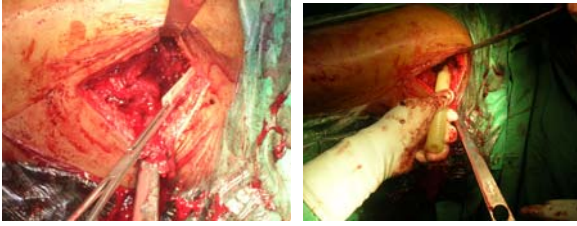


Figure 7. Technique of reduction of the fracture, fixation and insertion of free fibular autostrutgraft

## EVALUATION

We conduct retrospective observational study of fibular autostrutgraft constructs as the treatment of the femoral neck fractures. Objective of this study is to evaluate the clinical outcome for this technique. We evaluate the result with the Hip Score. Hip Score including pain, range of hip movement, ability to work and leg length discrepancy. The result were classified as excellent, good, fair or poor. Anteroposterior and axial radiographs of the hip were also assessed and obliteration of the fracture site with trabecular bridging was taken as evidence of union.

### NEGLECTED FRACTURE OF THE FEMORAL NECK

Table I. Criteria for grading the results

Grade	Clinical features			Walking ability	Radiological features		
	Pain	Shortening (cm)	Hip ROM*		AVN	Nonunion	Coxa vara (degrees)
Excellent	None	<1	Full	Full	No	None	None
Good	None	1 to 2	Rotation/flexion restricted by 15°	Full	No or healed	None	<10
Fair	Intermittent	2 to 3	Rotation <50% Flexion 90° only	1 km without aids	AVN No segmental collapse	None	11 to 20
Poor†	Constant	>3	Marked restriction	None without aids	AVN with collapse	Present	>20

\* range of movement

† presence of any two clinical plus one radiological criteria, or two radiological and one clinical criteria classified the result as poor

At the last 3 years we treat 15 patients with neglected femoral neck fracture by cancellous screw fixation and free fibular autostrutgraft construct. 10 patients were

found to be united and the other was still in observation. For that 10 patients, we evaluate with Hip Score.

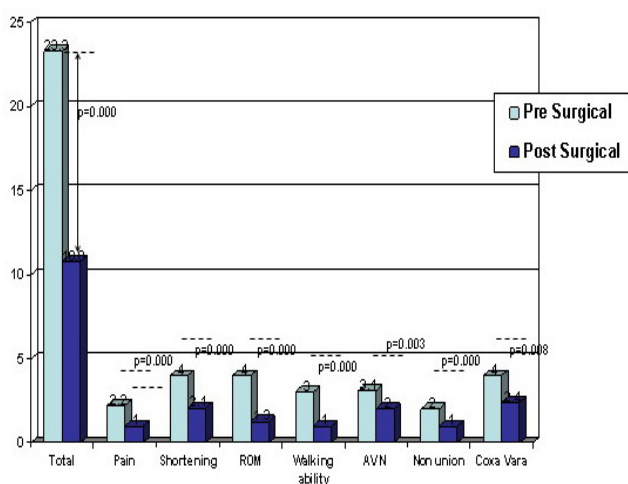
## RESULT

Name	Pain		Leg Length Discrepancy (Shortening)		ROM of the Hip		Walking Ability		Avascular Necrosis (AVN)		Non Union		Coxa Vara		Hip Score
	Pre	Post	Pre	Post	Pre	Post	Pre	Post	Pre	Post	Pre	Post	Pre	Post	
Martopo	Intermittent	None	4 cm	1 cm	0°- 45°	0°-110°	None without aids	Full	+	+ No segmental collapse	+	None	45°	30°	Good
Abdi Maulana	Intermittent	None	3 cm	0,5 cm	0°- 50°	Full	None without aids	Full	+	Healed	+	None	30°	None	Excellent
Adi Ista	Intermittent	None	5 cm	4 cm	0°- 45°	Full	None without aids	Full	+	+ No segmental collapse	+	None	45°	45°	Poor
Yoyok Sutikno	Intermittent	None	3 cm	No	0°- 45°	0°- 90°	None without aids	Full	+	Healed	+	None	30°	None	Good
Sugiat	Constant	None	3 cm	None	0°- 20°	Full	None	Full	No	No	+	None	30°	None	Excellent
Soni Agus	Intermittent	None	5 cm	2 cm	0°- 45°	Full	None without aids	Full	+	+ No segmental collapse	+	None	45°	30°	Good
Teguh Cahya	Intermittent	None	3 cm	None	0°- 45°	Full	None without aids	Full	+	Healed	+	None	45°	None	Excellent
Muriska	Constant	None	4 cm	2 cm	0°- 20°	Full	None	Full	No	No	+	None	45°	30°	Excellent
Edi Susanto	Intermittent	None	4 cm	1 cm	0°- 45°	Full	None without aids	Full	No	No	+	None	30°	None	Excellent
Dimas	Intermittent	None	4 cm	2 cm	0°- 45°	Full	None without aids	Full	+	Healed	+	None	45°	20°	Excellent

## Descriptive statistics

	N	Range	Mean $\pm$ SD
Age (years)	10	15-55	28.60 $\pm$ 14.55
Mean period of delay (month)	10	1-24	9.75 $\pm$ 8.46
Post surgical to follow up	10	5-36	14.40 $\pm$ 8.51
Pre surgical hip score	10	21-24	23.30 $\pm$ 1.16
Post surgical hip score	10	7-15	10.80 $\pm$ 2.97
Pre surgical pain score	10	2-3	2.20 $\pm$ .42
Post surgical pain score	10	1	1.00 $\pm$ .00
Pre surgical shortening score	10	4	4.00 $\pm$ .00
Post surgical shortening score	10	1-4	2.10 $\pm$ 1.10
Pre surgical ROM score	10	4	1.30 $\pm$ .68
Post surgical ROM score	10	1-3	3.00 $\pm$ .00
Pre surgical walking ability score	10	3	1.00 $\pm$ .00
Post surgical walking ability score	10	1	3.10 $\pm$ 1.45
Pre surgical avascular necrosis score	10	1-4	2.00 $\pm$ .82
Post surgical avascular necrosis score	10	1-3	2.00 $\pm$ .00
Pre surgical non union score	10	2	2.00 $\pm$ .00
Post surgical non union score	10	1	1.00 $\pm$ .00
Pre surgical coxa vara	10	4	4.00 $\pm$ .00
Post surgical coxa vara	10	1-4	2.40 $\pm$ 1.51

## Paired samples statistics



## CONCLUSION

There are significance improvement of the union rate and hip function of the patients with femoral neck fracture that treated by compression screw fixation and fibular autograft technique. From the clinical and radiological finding we suggest that the fibular graft provide structural support and promote union, indirectly contributes to revascularisation of the femoral head. As long as the femoral head is saved and union achieved, shortening or marked coxa vara may be corrected by abduction osteotomy at a later stage. We recommend this procedure for the treatment of femoral neck fracture,

especially for neglected fractures in young adults to reduce resorption of the neck, AVN and non union.

## REFERENCES

- Black, J 1988, *Orthopaedic Biomaterials in Research and Practice*, Churchill Livingstone, New York, NY, pp. 23-29.
- Chapman, MW 2001, 'Bone grafting, bone graft substitute and growth factor', in *Chapman's Orthopaedic Surgery*, 3rd edn, Lippincott William-Wilkins, pp. 237-249
- Clarke, SA et al. 2004, 'Bone growth into a ceramic-filled defect around an implant - the response to transforming growth factor beta1', *The Journal of Bone & Joint Surgery*, vol. 86(B), pp. 126-134.
- Crenshaw. AH. MD, (1992), "Fracture of the Hip" in *Campbell's Operative Orthopaedics* 2nd vol, 8th ed., Mosby Year Book, p735-37.
- Jupiter, B et al. 1998, 'Intracapsular hip fracture', in *Browner, Skeletal Trauma*, 4th edn, WB Saunders Company, pp. 125-135
- Nagi, O, Dhillon, MS, et al. 1998, 'Open reduction, internal fixation and fibular autografting for neglected fracture of the femoral neck', *J Bone Joint Surg*, [Br] vol. 80B, pp. 798-804
- Rockwood, CA, Wilkins, KE, King, RE 1991, 'Femoral Neck Fracture', in *Rockwood, Fracture in Adults*, 1st vol, 3rd edn, JB Lippincott Company, pp. 187-203.